Peristomal Pyoderma Gangrenosum: Achieving Success in Wound Healing in an Environment of Competing Priorities

Lindsay L. Balderas-Baca BSN, RN, CWOCN, CFCN and David M. Mercer DNP, ACNP-BC, CWOCN, CFCN

Introduction

Pyoderma Gangrenosum (PG) is a rare, painful ulcerative skin disease often associated with underlying systemic processes such as Inflammatory Bowel Disease (IBD). The scarcity of treatment regimens for PG and the additional complexity of concomitant stoma management present a unique challenge for treating clinicians.

HPI

A middle aged male with IBD presented with c/o of peristomal skin lesions. Physical exam revealed ten extremely painful, well circumscribed full thickness lesions draining purulent exudate and interfering with ostomy appliance adherence. Of note, he had a large non healing perianal wound (PG) for which a transverse colostomy was created eight months prior.

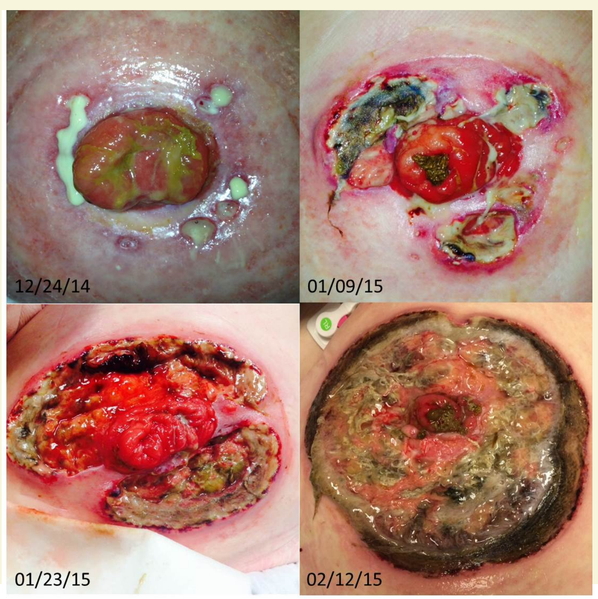

Outpatient Management

At initial presentation in the outpatient setting, patient was initiated on oral steroids (60 mg prednisone daily). Three weeks later the wounds demonstrated significant progression and dermatology was consulted. Topical steroid (clobetasol 0.05%) use and oral cyclosporine were initiated in addition to prednisone. Significant tremors and elevation in creatinine necessitated the discontinuation of cyclosporine. Ultimately, the patient was unable to maintain adherence of an ostomy appliance. Within one month of initial presentation, the peristomal wound had advanced to approximately 15cm x 20cm. After two months of failed conservative outpatient treatment, patient was admitted to a tertiary academic health system for aggressive multidisciplinary evaluation and treatment.

Inpatient Management

Gastroenterology initiated infliximab infusion and high dose IV pulse methylprednisolone. Local wound management included a TIW NPWT[1] regimen. Initial applications of NPWT required pulse lavage and conservative sharp debridement of grossly necrotic wound borders. Topical wound therapy included Clobetasol 0.05%, an enzymatic debridement ointment,[2] a silicone non adherent contact layer,[3] and a stoma isolation device.[4] Within one week of admission, no pathergy was noted. Two weeks after admission, the wound bed was greater than 50% granulation tissue and an ovine collagen extracellular matrix dressing[5] was utilized in addition to the NPWT regimen. Four weeks after admission, the wound bed was nearly 100% granulation tissue.

Surgical Intervention

With adequate wound bed preparation, Plastic surgery colleagues were consulted for consideration of split-thickness skin grafting (STSG). Allograft was selected and placed on patient due to high risk for graft failure. A silicone non-adherent contact layer and NPWT were reapplied in the OR and left in place for one week. Patient returned to OR for STSG autograft with reapplication of the NPWT. Patient was discharged from hospital after one week and continued NPWT in outpatient setting. The skin graft was well adherent with greater than 90% graft take at time of follow up.

Outpatient Follow Up

WOCN continued to follow patient after discharge for alternative ostomy appliance management until complete graft healing. Maintenance infliximab was initiated and oral steroids tapered.

Implications For Practice

Aggressive management plans are often required for the effective treatment of patients with complex wound care needs. In today's compartmentalized healthcare environment, it is critical to coordinate effectively with multiple disciplines in order to address the patient's needs.

This case highlights the importance of multidisciplinary collaboration, industry support, and forming a goal-oriented partnership with your patient.

1. NPWT, KCI/Acelily
2. Collagenase, Smith and Nephew, Inc.
3. Mepitel, MÖlnlycke Health
4. Wound Crown, fistulasolutions.com
5. Endoform Dermal Template, Hollister Inc.